

THE DENTAL ADVISOR

"Improving Patient Care Through Research & Education"

EDITORS

John W. Farah, D.D.S., Ph.D.
John M. Powers, Ph.D.

ASSOCIATE EDITORS

William A. Gregory, D.D.S., M.S.
Peter Yaman, D.D.S., M.S.
Lori K. Brown, D.D.S.
Santine E. Anderson, D.D.S.
Charles I. McLaren, D.D.S., M.S.
Sabiha S. Bunek, D.D.S.

ASSISTANT EDITORS

Mert N. Aksu, D.D.S., M.H.S.A.
Mark T. Waranowicz, D.D.S., M.S.
William T. Stevenson, D.D.S.
Robert Stevenson, D.D.S.

Nizar Mansour, D.D.S.
Kathy L. O'Keefe, D.D.S., M.S.
Brent Kolb, D.D.S.
David Traynor, D.D.S.

EXECUTIVE TEAM

Annette M. Frederick
Jennifer Kalasz
Jennifer B. Lill, M.A.Ed.
Tricia G. Price
Rhonda L. Tucker
Mary E. Yakas, B.A., CMC
Ron Yapp, M.S.

GRAPHIC DESIGNER

Pari Karani, B.S., M.S.

PUBLISHER

Dental Consultants, Inc.
Please send inquiries and address changes to:

THE DENTAL ADVISOR,

3110 West Liberty, Ann Arbor, MI 48103
Call: 800.347.1330 • 734.665.2020
Fax: 734.665.1648
Email: info@dentaladvisor.com
Website: www.dentaladvisor.com

Copyright ©2009, Dental Consultants, Inc. All rights reserved.
Printed in the U.S.A.
(ISSN 0748-4666)

NUMBER 10 • APRIL 2009

3M ESPE Lava Chairside Oral Scanner C.O.S. John W. Farah, D.D.S., Ph.D.; Carol Reed; Debbie Wojtowicz Enspire Dental, Ann Arbor, MI, USA

Introduction

The *Lava™ Chairside Oral Scanner C.O.S.* from 3MESPE is used to capture high accuracy scans of patient teeth. Data from the scan are used to create an articulated stereolithography (SLA) model that a dental laboratory uses to design restorations such as crowns, inlays, onlays, and bridges.

The *Lava C.O.S.* has a scanning wand that contains a single primary lens that captures images at video rate on three sensors. It delivers 20, 3-D data sets per second using patented wavefront sampling technology¹. The wand cable is connected to a cart that houses the CPU, which models the data in real time and displays it on a touch-screen monitor. The touch screen is also used to manipulate the virtual model and interact with the system software to enter patient information and information relevant to the preparation.

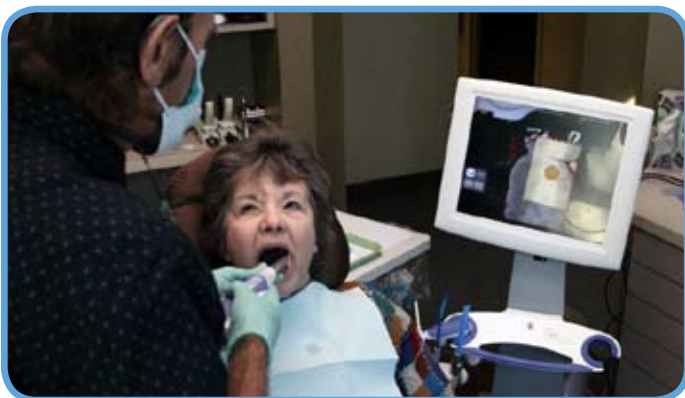


Fig 1 Scanning

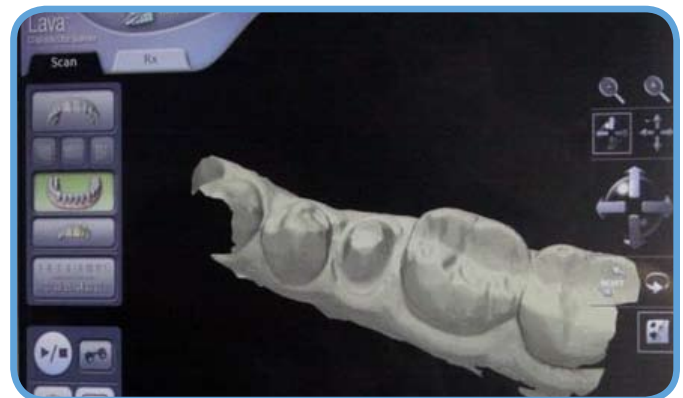

Fig 2 Display

Treatment Plan

A 51-year-old female patient presented to the office complaining of tenderness to biting pressure emanating from the upper left quadrant. Upon examination it was determined that the discomfort originated in tooth #13. The tooth had a large MOD amalgam. The patient was anesthetized and the amalgam removed. A crack was discovered at the base of the lingual cusp. Due to the size of the amalgam and the crack, a composite core and crown was recommended to the patient.

1 Rohaly J. et al. (2006, SEP) Three-channel camera systems with non-collinear apertures, United States Patent 7,372,642

The patient agreed to the treatment. Following caries removal, a composite core was bonded to the tooth (*LuxaBond Total Etch/LuxaCore Z Dual*, Zenith Dental/DMG). The tooth was prepared for a full crown restoration with a chamfer margin. The axial walls were reduced by 1-1.5 mm, and the occlusal surface by 1.5-2.0 mm. This tooth reduction is consistent with recommendations made for *Lava* zirconia crowns. Upon completion of the preparation a #1 retraction cord (*Ultradent #00*) was packed in the sulcus for optimal visualization of the margins.

Scanning and Impressioning

A thin dusting with titanium dioxide powder was applied to the upper left quadrant to facilitate the scanning of the preparation and the adjacent teeth. The application of the powder is very light and in most cases barely perceptible to the eye. Once the powder was applied, the prepared tooth was scanned. After verification that the margins were clearly visible and all details of the preparation were captured, and the remainder of the quadrant was scanned beginning with the occlusal surfaces, then the labial and finally the lingual surfaces. A similar scan was done of the opposing quadrant and finally a scan of the teeth in occlusion. The scans were individually checked for completeness before their acceptance. The average time to obtain the entire scan was about 5 minutes.

A lab prescription for a *Lava* zirconia crown was completed on the system, and the case was sent electronically to Apex Dental Milling for margin marking. A traditional impression using a PVS impression material (*Aquasil Ultra* heavy and light viscosities, *DENTSPLY Caulk*) with a dual-arch tray was also taken, and stone models were prepared by the dental laboratory.

For purposes of comparison, two *Lava* zirconia crowns were fabricated: one derived from the digital impression and one derived from the traditional impression.

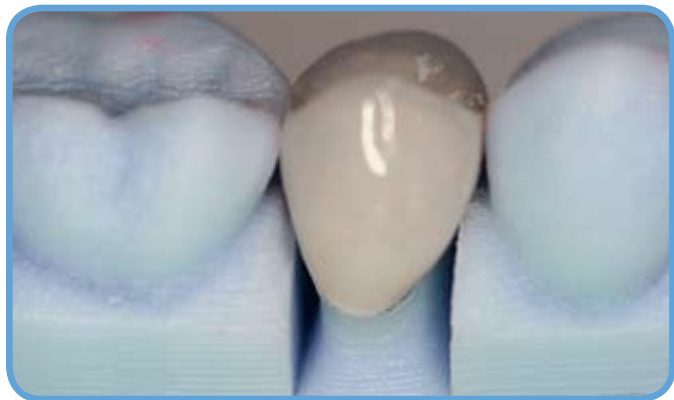

Fig 3 SLA Model

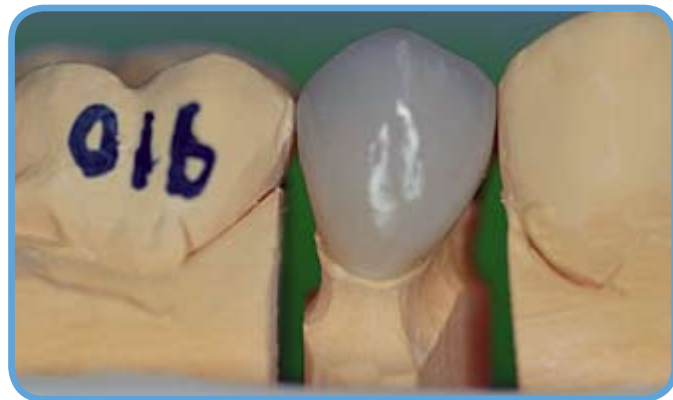

Fig 4 Traditional Model

Each crown was carefully checked on its respective die, then on the opposite die, and on the actual tooth. The crowns were evaluated for fit, stability, esthetics, occlusion, and the quality of the mesial, distal, lingual, and facial margins. The crown with the best fit and accuracy was cemented intraorally.

Crown Selection and Cementation

Two crowns were fabricated; one on the SLA model and the second on the traditional impression model. Each crown fit its respective die very well, were stable and the margins fit extremely well. The crowns were interchanged on the dies and the fit was still good although the crown made on the SLA model was not flush at the facial margin of the stone die (*see figure 4*). It was determined that the stone die was not properly trimmed. The SLA crown was chosen based on the buccal, lingual, mesial and distal marginal adaptation and fit on the natural tooth. The SLA crown was cemented with *Rely X Unicem Self-Adhesive Universal Resin Cement* (3M *ESPE*).

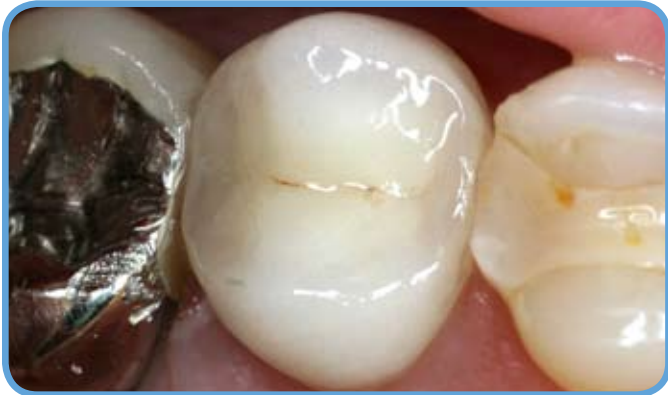

Fig 5 Final Restoration

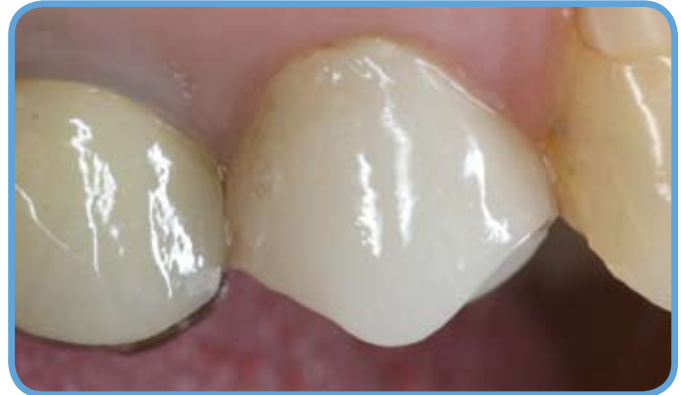

Fig 6 Final Restoration

Observations on Scanning

The patient was a severe gagger and had little tolerance for anything in her mouth which makes a traditional impression very challenging. However, the scanning process was explained to the patient, assuring her that the process could be stopped anytime if she became uncomfortable. A dry angle was placed on the internal aspect of the cheek. A thin dusting of powder was applied to the upper left quadrant and scanning commenced. The scan went very smoothly and the patient did not gag at any time. The lower quadrant was scanned, followed by the buccal aspect of the teeth in centric occlusion. The scans were quick, ran smoothly, and the patient did not experience any discomfort. The net scanning time of all three scans totaled about 5 minutes. The patient was ecstatic and commented that she was pleasantly surprised at how easy the process was.

Patient Observations and Comments

- “The scan is so much easier than the impression. I would rather have the scan any day in place of the regular impression.”
- “I don’t like the feeling of an impression tray when I bite down. It is uncomfortable.”
- “Can we do this every time, I don’t like impressions.”
- “Loved it! Incredible! Nothing to it. This is exciting technology!”

Doctor Comments

- “When patients were asked which system they prefer, the scan or the impression, ninety percent preferred the scanning over the impression.”
- “It took fifteen to twenty scans to get very comfortable with the C.O.S. After the learning curve, the scan time was, in general, around four to five minutes.”
- “I feel that this technique is very viable and can be easily included in the day-to-day clinical operation of the office.”

Assistant Comment

- “Patients don’t feel trapped with the scanning. If there is any problem it can be stopped at any time, and you can return to scanning. With a traditional impression, the patient cannot open until the material hardens.”

Conclusion

The *Lava™ Chairside Oral Scanner C.O.S.* from 3M ESPE was easily incorporated into a busy dental practice and was very well received by the patient. The patient preferred the scan to the traditional impression. The digital impression also proved to be more accurate than the traditional method.